

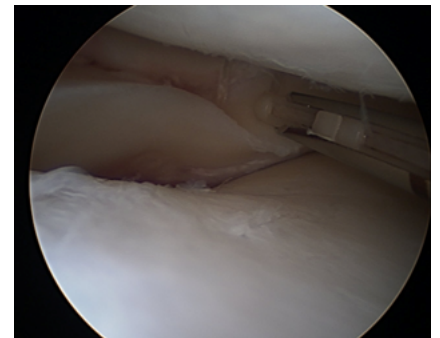
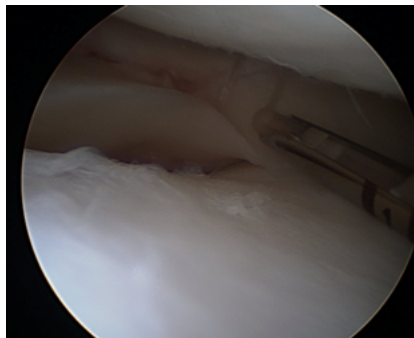
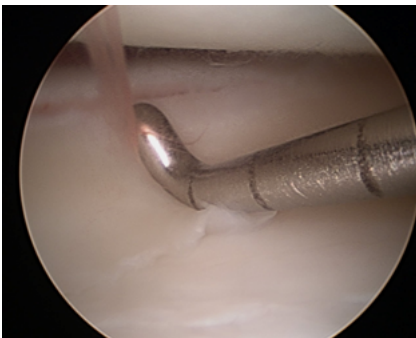
Sequent™ Meniscal Repair Device

Surgeon Testimonial:

Sequent Repair in Patient “Well-Healed” at Two Months

- Alan Barber, MD
July 13th, 2011

On May 11th of this year, I performed a lateral meniscus repair using the Sequent device.



On July 13th, I went back into the patient's knee to perform the ACL reconstruction and was pleased to find a well-healed meniscus.

